

Risk factors and treatments for hepatic arterial complications in pediatric living donor liver transplantation

Yukihiro Sanada · Taiichi Wakiya · Shuji Hishikawa ·
Yuta Hirata · Naoya Yamada · Noriki Okada ·
Yoshiyuki Ihara · Taizen Urahashi · Koichi Mizuta ·
Eiji Kobayashi

Published online: 20 October 2013

© 2013 Japanese Society of Hepato-Biliary-Pancreatic Surgery

Abstract

Background Hepatic artery complications (HAC) are a serious complication in pediatric liver transplant recipients because its incidence is high and it can occasionally lead to graft liver failure. We herein present a retrospective analysis of our 10-year experience with pediatric living donor liver transplantation (LDLT) focusing on the risk factors and treatments for HAC.

Methods Between May 2001 and November 2011, 209 LDLTs were performed for 203 pediatric recipients. We performed the multivariate analyses to identify the factors associated with HAC and showed the therapeutic strategy and outcome for HAC.

Results The overall incidence of HAC was 7.2%, and the graft survival of recipients with HAC was 73.3%. The multivariate analysis showed that the pediatric end-stage liver disease score (≥ 20), post-transplant laparotomy except for HAC treatment and extra-anatomical hepatic artery reconstruction were independent risk factors for HAC ($P = 0.020$, $P = 0.015$ and $P = 0.002$, respectively). Eleven surgical interventions and 13 endovascular interventions were performed for 15 recipients with HAC. The serum aspartate aminotransferase levels pre- and post-treatment for HAC were significantly higher in the surgical group than in the endovascular group ($P = 0.016$ and $P = 0.022$, respectively).

Conclusions It is important for recipients with risk factors to maintain strict post-transplant management to help

prevent HAC and detect it in earlier stages. Endovascular intervention can be a less invasive method for treating HAC than surgical intervention, and can be performed as an early treatment.

Keywords Endovascular intervention · Extra-anatomical hepatic artery reconstruction · Hepatic arterial complications · Pediatric living donor liver transplantation · Post-transplant laparotomy

Introduction

Liver transplantation (LT) is an established curative therapy for pediatric patients with end-stage liver disease or acute liver failure. However, hepatic artery complications (HAC) can be a serious complication in LT recipients, occasionally leading to graft liver failure or even death. The cause of HAC is multifactorial, but is often related to kinking or anastomotic stenosis as a result of the transplant surgery. The reported incidence of HAC is 4.4%, being 8.3% in children and 2.9% in adults [1]. The most likely explanation for the higher incidence in pediatric recipients is the small size of the vessels and the narrow abdominal cavity, which create technical difficulties related to the vessel anastomosis [2, 3]. The suggested risk factors for HAC after LT include a low body weight, metabolic disease, re-LT, the use of arterial conduits and variant arterial anatomy [1–3]. However, few studies have analyzed the risk factors for HAC in pediatric recipients, and no consensus has yet been reached. Therefore, in order to reduce the incidence of HAC in pediatric recipients, it is important to clarify the risk factors for HAC and to devise more suitable hepatic arterial reconstruction methods.

Hepatic artery complications after pediatric LT is a serious complication resulting in bile duct necrosis and often requiring retransplantation. Therefore, an early

Y. Sanada (✉) · T. Wakiya · Y. Hirata · N. Yamada · N. Okada ·
Y. Ihara · T. Urahashi · K. Mizuta
Department of Transplant Surgery, Jichi Medical University, 3311-1
Yakushiji, Shimotsuke, Tochigi 329-0498, Japan
e-mail: yuki371@jichi.ac.jp

S. Hishikawa · E. Kobayashi
Center for Development of Advanced Medical Technology, Jichi
Medical University, Shimotsuke, Tochigi, Japan

diagnosis and treatment are essential. There are currently two major therapeutic options for HAC: surgical and endovascular interventions. Immediate surgical thrombectomy or thrombolysis has been reported to be a potentially successful treatment for restoring the blood flow and avoiding urgent retransplantation [4–6]. On the other hand, endovascular interventions have emerged as an attractive and less invasive alternative to surgical interventions in recent years [7–14]. However, endovascular interventions remain controversial in view of the potential risks of hemorrhage in the early postoperative period and uncertain long-term patency. We have reported that endovascular intervention in the early postoperative period was safer and less invasive than surgical intervention [9–11], and other transplant surgeons have reported that endovascular interventions can lead to a successful mid-term patency [12–14].

In recent years, the number of classical hepatic artery thrombosis cases has decreased because of the ability to perform an early diagnosis and treatment by endovascular interventions. Post-transplant complications associated with the hepatic artery also include the compressive or spastic artery hypoperfusion due to hematoma or abscess. Therefore, we substituted the expression “HAC” for “hepatic artery thrombosis” in this study.

We herein present a retrospective analysis of our 10-year experience with pediatric living donor liver transplantation (LDLT) at a single center in Japan. Special attention was given to the analysis of the risk factors and treatments for HAC in our series of 209 cases.

Patients and methods

Patients

Between May 2001 and November 2011, 209 LDLTs were performed for 203 pediatric recipients with end-stage liver disease or acute liver failure at the Department of Transplant Surgery, Jichi Medical University, Japan. The demographic data for the recipients and information on the grafts are given in Table 1. All recipients or families of recipients were informed about the study and their consent was obtained before LDLT.

Surgical procedures for LDLT

The type of donor hepatectomy was determined according to the recipient standard liver volume or body weight. If the donor left lobe, as estimated using preoperative computed tomographic volumetry, was less than 40% of the recipient standard liver volume, a left plus caudate graft hepatectomy or recipient splenectomy was performed. The donor biliary anatomy was evaluated using either intraoperative repeated

Table 1 Demographic data for recipients and grafts

Gender	Male	79 (37.8%)
	Female	130 (62.2%)
Body weight (kg)		9.8 (2.6–65.0)
Age (months)		19 (0–234)
Original disease (cirrhosis)	Biliary atresia	153 (73.2%)
	Alagille syndrome	9 (4.3%)
	Others ^a	9 (4.3%)
(Non-cirrhosis)	Ornithine transcarbamylase deficiency	16 (7.6%)
	Graft liver failure	8 (3.8%)
	Fulminant hepatic failure	6 (2.9%)
	Congenital extrahepatic portosystemic shunt	4 (1.9%)
	Neonatal hemochromatosis	2 (1.0%)
	Carbamoyl-phosphate synthase 1 deficiency	1 (0.5%)
	Hepatoblastoma	1 (0.5%)
	Graft type	II + III
	II + III + IV	44 (21.1%)
	I + II + III + IV	9 (4.3%)
	II	7 (3.3%)
	Reduced II + III	4 (1.9%)
Graft weight (g)		245 (93–600)
GV/SLV (%)		74.6 (33.0–130.0)
GRWR (%)		2.4 (0.7–4.3)
ABO blood type	Identical	139 (66.5%)
	Compatible	37 (17.7%)
	Incompatible	33 (15.8%)

GRWR graft-to-recipient weight ratio, GV/SLV graft volume-to-standard liver volume ratio

^a Others: Wilson disease in three, liver cirrhosis in two, primary sclerosing cirrhosis in two, Byler disease in one, cystic fibrosis in one

real-time cholangiography or preoperative magnetic resonance cholangiography. A routine donor graft hepatectomy was performed using intraoperative ultrasonic guidance. The donor hepatic artery without over-detachment was transected using sharp scissors (Metzenbaum). After donor left lobectomy, V5 or V8 reconstruction of the remnant liver was performed using a donor intra-abdominal vein (e.g., the ovarian vein) in patients with an enlarged V5 or V8. The allograft was preserved with University of Wisconsin solution (Viaspan). If necessary, graft hepatic vein venoplasty was performed on the back table. If the actual left lateral segment resected was greater than 120% of the recipient standard liver volume, an *ex vivo* partial reduction from the distal side of the graft was performed. For neonatal recipients, we used a segment 2 monosegment graft, as reported previously [15].

Fig. 1 Hepatic arterial reconstruction using a single clip (a) or a double clip (b). *LHA* left hepatic artery, *RHA* right hepatic artery

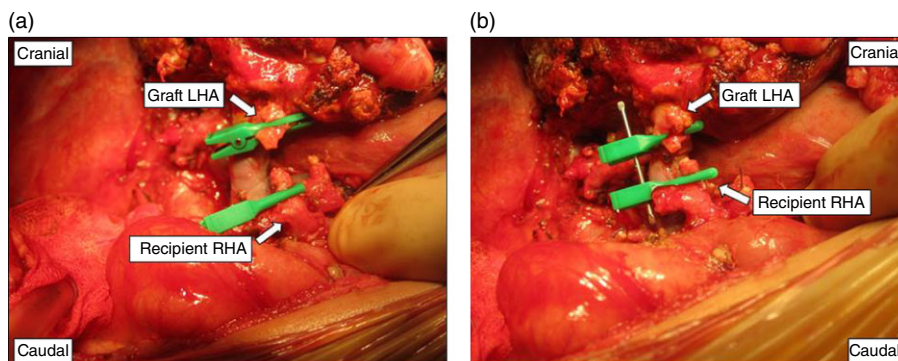
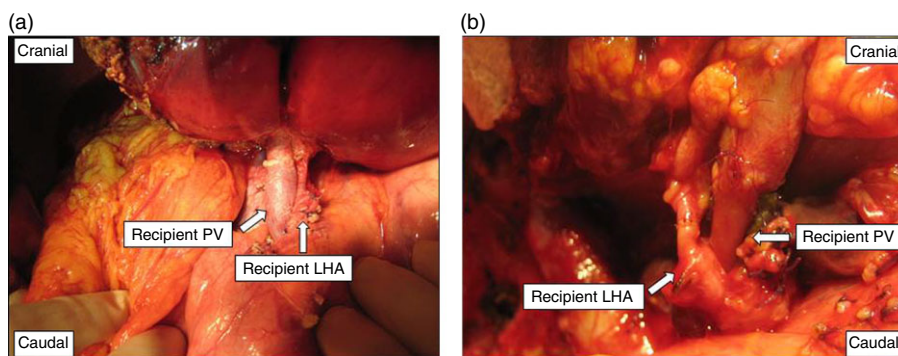


Fig. 2 A typical anastomotic field in hepatic arterial reconstruction: the ventral location of the portal vein anastomosis. *LHA* left hepatic artery, *PV* portal vein, *RHA* right hepatic artery



For the recipient operation, a Mercedes-Benz or transverse incisions were made, and total hepatectomy was performed. The recipient hepatic artery without over-detachment was transected in the location of the second branch of the hepatic artery. In many infants, after total hepatectomy, the recipient right, middle and left hepatic veins were formed into a single orifice, which was then anastomosed end-to-end to the graft left hepatic vein, and the portal vein was reconstructed between the recipient right or left portal vein branch patch and the graft left portal vein. Hepatic artery reconstruction was performed using microsurgical techniques. Biliary reconstruction was performed using a Roux-en-Y hepaticojejunostomy. Intraoperative color Doppler ultrasonography was performed to assess the blood flow velocity and pattern after vascular reconstruction, and during abdominal wall closure.

Hepatic arterial reconstruction

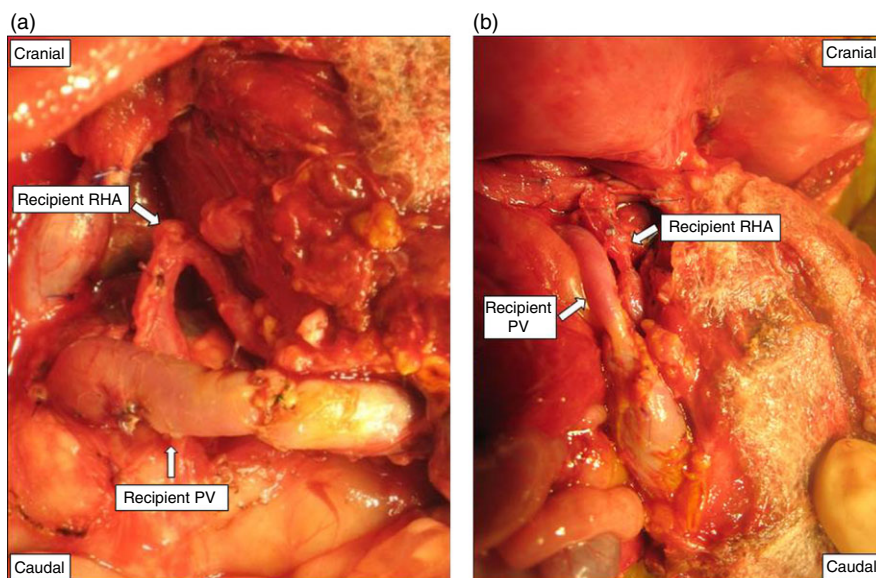
All of the hepatic artery reconstruction was performed using interrupted 9-0 monofilament nylon (Keisei Medical Industrial, Tokyo, Japan) sutures on the anterior and posterior wall under a microscope. The recipients who underwent LDLT between May 2001 and September 2008 underwent a hepatic arterial reconstruction using a single clip (TKM-1, Bear Medic Corporation, Tokyo, Japan) (Fig. 1a), and the recipients who underwent LDLT from October 2008

onwards underwent a hepatic arterial reconstruction using a double clip (TKM-2, Bear Medic Corporation) (Fig. 1b). Almost all of the anastomotic fields used during the hepatic arterial reconstruction were the ventral location of the portal vein anastomosis (Fig. 2), but in a few cases, especially in neonates, the field was the dorsal location of the portal vein anastomosis (Fig. 3) because hepatic arterial reconstruction would have been very difficult when the anastomotic position was tangential or the anastomotic fields were narrow. In the case of a graft hepatic artery with two orifices, after reconstruction of the dominant graft artery, if back flow was observed from the remnant graft artery or all the intrahepatic arterial flow was confirmed using intraoperative Doppler ultrasonography, the reconstruction of the remnant graft artery was not performed.

Immunosuppression therapy

Tacrolimus (Tac) and methylprednisolone (MP) were used as the standard postoperative immunosuppression therapy. The target trough level of Tac and MP was gradually decreased. Mycophenolate mofetil was used when more potent immunosuppression was required, for example, in ABO-incompatible recipients older than 5 years, in patients with steroid-resistant acute rejection episodes, and also in patients with liver dysfunction after the cessation of MP therapy.

Fig. 3 An atypical anastomotic field in hepatic arterial reconstruction: the dorsal location of the portal vein anastomosis, which is especially common in neonates. *PV* portal vein, *RHA* right hepatic artery



Post-transplant management and anticoagulation treatment

During the post-transplant period, we routinely performed anticoagulation treatment and Doppler ultrasonography. Anticoagulation treatment was started by using intravenous dalteparin sodium (100 U/kg per day) from a few postoperative days (POD). When the hepatic arterial flow was considered to be low, we increased the anticoagulation treatment by increasing the dose of dalteparin sodium and/or adding the intravenous administration of urokinase at a total dose of 90,000–180,000 units/day, adjusted with reference to the activated clotting time (target level: 180–200 s) and/or the activated partial thromboplastin time (target level: 50–70 s). If hepatic arterial flow is sufficient, we usually withdraw the anticoagulant treatment at POD 14.

In our department, the imaging surveillance methods used for follow-up were Doppler ultrasonography and contrast enhanced computed tomography. Doppler ultrasonography was performed routinely twice per day until hospital discharge, and thereafter at 1, 3, 5 and 9 months and then every 6 months after LDLT. Contrast-enhanced computed tomography was performed routinely at 2, 6 and 12 months and then every 12 months after LT.

Diagnosis of HAC and therapeutic strategy for HAC

We considered the hepatic arterial flow to be low and suspected the presence of HAC when the peak systolic velocity was less than 20.0 cm/s or the resistive index was less than 0.6 just distal to the anastomosis site as revealed by Doppler ultrasonography. Since December 2004, percutaneous transfemoral angiography has been carried out under general anesthesia for the diagnosis and treatment of HAC

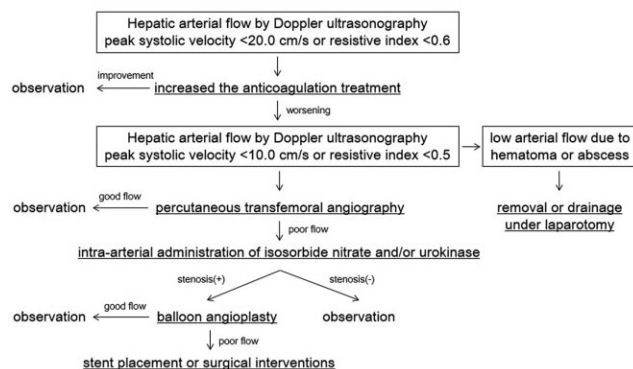


Fig. 4 The therapeutic strategy used for hepatic artery complications in our department

when the peak systolic velocity was less than 10.0 cm/s and the resistive index was less than 0.5. When we diagnosed HAC, we performed surgical and endovascular interventions based on Figure 4.

If compressive or spastic artery hypoperfusion due to hematoma or abscess were not suspected, we selected endovascular interventions. We think the only exclusion criterion should be such a compressive or spastic artery hypoperfusion by a hematoma or abscess, and do not believe that age is a contraindication. A 4 Fr sheath (Super sheath, 4 Fr, 10 cm; Medikit, Tokyo, Japan) was placed through the femoral artery by cut-down or ultrasonography-guided percutaneous puncture methods. An ultrasonography-guided percutaneous puncture method was carried out by radiologists, and a cut-down method was performed by transplant surgeons. We performed celiac arteriography with a 4 Fr angio-catheter (Glidecath, 4 Fr, 70 cm; Cobra, Terumo, Tokyo, Japan) and established a diagnosis of HAC.

If angiography revealed a decrease or disappearance of arterial blood flow through the anastomotic site, the first

treatment was the intra-arterial administration of isosorbide nitrate and/or urokinase (total dose 5,000–20,000 units, adjusted according to the findings). Prior to beginning endovascular interventions, the recipients received heparin (5,000 units). When stenosis was subsequently noted at the anastomotic site by angiography (the luminal diameter of the hepatic artery decreased by more than 50%), we performed balloon angioplasty using a balloon catheter. A micro-guidewire (Silverspeed-10, 0.010 inch, 200 cm; EV3, Irvine, CA, USA) was first advanced into the graft left hepatic artery, and then a microcatheter (Microferret-18, 2.4 Fr, 130 cm; COOK, Bloomington, IN, USA) was inserted along the micro-guidewire into the intrahepatic artery. Balloon angioplasty was then performed using a percutaneous transluminal coronary angioplasty balloon catheter. Until 2007, the Ryujin Plus balloon (2.4 Fr, 145 cm, semicompliant balloon; Terumo) was selected as the balloon catheter. Since 2007, the IKAZUCHI-X balloon (2.1 Fr, 130 cm, semicompliant balloon; Kaneka, Osaka, Japan), capable of passing through the lumen of the guide catheter (an angio-catheter), has been used. The balloon size was selected based on the diameter of the hepatic artery distal to the stenosis. After balloon angioplasty, if the artery contributed to have poor flow, we performed stent placement using a metallic stent (MULTI-LINK MINI VISION stent, bare metal, balloon expandable type; Abbott, Abbott Park, IL, USA) or surgical interventions. Following stent placement, antiplatelet medication (acetylsalicylic acid, 2 mg/kg per day) was administered to prevent thrombosis for at least 3 months. The success of endovascular interventions was defined as a peak systolic velocity more than 20.0 cm/s or a resistive index higher than 0.6.

If compressive or spastic artery hypoperfusion due to hematoma or abscess was suspected, we selected surgical interventions. In addition, based on our department policy, if endovascular interventions were not possible or efficacious, we did not hesitate to convert the procedure to a surgical intervention. Surgical interventions were classified as re-anastomosis by anastomotic site opening and anastomosis, removal or drainage of hematoma or abscess under laparotomy or surgical thrombectomy using a Fogarty embolectomy catheter via another non-anastomotic hepatic artery.

The one cause of HAC was an anastomotic stenosis due to either the surgical technique or anastomotic thrombosis and kinking, and the other was compression or spasm due to hematoma or abscess.

Statistical analysis

The significance of differences between two groups was evaluated using the χ^2 test. Associations between the recipi-

Table 2 Demographic data for graft and recipient's hepatic artery

Number of anastomosis at LDLT	One anastomosis	195 (93.3%)
	Two anastomosis	14 (6.7%)
Total number of anastomosis		223
Diameter of graft hepatic artery (mm)		2.2 ± 0.5
Graft artery type	Lha	183 (82.1%)
	Accessory LHA	19 (8.5%)
	Mha	10 (4.5%)
	Others ^a	11 (4.9%)
Diameter of recipient hepatic artery (mm)		2.3 ± 0.5
Recipient hepatic artery type	Rha	120 (53.8%)
	Lha	51 (22.9%)
	Pha	10 (4.4%)
	RHA (anterior)	7 (3.1%)
	RHA (posterior)	7 (3.1%)
	Branch patch ^b	7 (3.1%)
	Mha	6 (2.7%)
	Accessory LHA	3 (1.3%)
	Interposition graft ^c	2 (1.0%)
	Cha	1 (0.5%)
	Ja	1 (0.5%)
Others ^d	8 (3.6%)	

CHA common hepatic artery, GDA gastroduodenal artery, GEA gastroepiploic artery, JA jejunal artery, LGA left gastric artery, LHA left hepatic artery, MHA middle hepatic artery, PHA proper hepatic artery, RHA right hepatic artery

^a Others; A2 in three, A3 in three, A4 in one, PHA in one, CHA in one, GDA in one, unknown in one

^b Branch patch; PHA+GDA in one, RHA+MHA+GDA in one, RHA+MHA+LHA in one, RHA+MHA in one, RHA (anterior) + RHA (posterior) in one, A2+A3 in one

^c Interposition graft; donor LGA in one, donor GEA in one

^d Others; unknown in eight

ent, graft, post-transplant complications or hepatic artery variables and HAC were evaluated using the univariate and backward selection multivariate Cox regression methods. Graft survival was calculated by the Kaplan–Meier product-limited method, and differences in survival between two groups were then compared using the log-rank test. All statistical analyses were performed using the StatView software package (SAS Institute, Cary, NC, USA), and differences with values of $P < 0.05$ were considered to be significant.

Results

The demographic data pertaining to the grafts and the recipient's hepatic artery are presented in Table 2. Among the 209 LDLTs, 14 recipients underwent hepatic arterial reconstruction of two orifices, and therefore, a total of 223 hepatic arterial reconstructions were included in this study.

The overall incidence of HAC was 7.2% (15/209). The impact of various recipient, graft, post-transplant complications and hepatic artery variables were assessed, and the results are summarized in Table 3. The univariate analysis showed that the body weight (<6 kg), number of LDLT procedures (≥ 2), pediatric end-stage liver disease (PELD) score (≥ 20), transfusion volume at LDLT (≥ 100 ml/kg), post-transplant laparotomy except for HAC treatment and extra-anatomical hepatic artery reconstruction were independent risk factors for HAC ($P = 0.022$, $P = 0.046$, $P = 0.001$, $P = 0.018$ and $P < 0.001$, respectively). As shown in Table 4, the multivariate analysis indicated that the PELD score (≥ 20), post-transplant laparotomy except for HAC treatment and extra-anatomical hepatic artery reconstruction were independent risk factors for HAC ($P = 0.020$, $P = 0.015$ and $P = 0.002$, respectively).

The treatments and outcomes in the 15 recipients who developed HAC are summarized in Table 5. The onset of HAC was median POD 8 (ranged from POD 3 to POD 27). Eleven surgical interventions and 13 endovascular interventions were performed for the 15 recipients with HAC. The surgical procedures for HAC were surgical thrombectomy in six recipients, removal of hematoma or abscess in three, and re-anastomosis in two recipients. The endovascular procedures for HAC were balloon angioplasty in 12 cases and stent placement in one case. The causes of HAC were anastomotic stenosis in 19 cases, spasm in three, and kinking in two cases.

There was no graft loss due to HAC among the recipients who underwent LDLT in our department. The graft survival of recipients who did and did not develop HAC was 73.3% (11/15) and 94.8% (184/194), respectively. The log-rank test showed that the cumulative graft survival rate of recipients without HAC was significantly higher than that of recipients with HAC ($P < 0.001$; Fig. 5). The causes of graft loss were death in eight recipients, hepatic vein stenosis in three, recurrence of fulminant hepatitis in one, intrahepatic bile duct stenosis due to antibody-mediated rejection associated with ABO-incompatible LDLT in one, and primary non-function in one recipient. The causes of death were hemophagocytic syndrome in three recipients, bowel perforation in two, intracranial hemorrhage in one, *Pneumocystis carinii* pneumonia in one, and encephalitis of unknown etiology in one patient.

The result of a comparison of the recipients who underwent surgical and endovascular interventions for HAC are shown in Table 6. The serum aspartate aminotransferase (AST) levels pre- and post-treatment for HAC were significantly higher in the surgical intervention group than in the endovascular intervention group ($P = 0.016$ and $P = 0.022$, respectively). The recurrence rate of HAC and the post-treatment biliary complication rate were not significantly different, and the graft survival rate of the endovascular

Table 3 Rate of hepatic arterial complication (HAC) associated with each general risk factor and surgical technique

Recipient and graft variables	Incidence of HAC (%)	P-value
Age		
<12 months ($n = 66$) vs. ≥ 12 months ($n = 143$)	12.1 vs. 4.9	0.060
Body weight		
<6 kg ($n = 13$) vs. ≥ 6 kg ($n = 196$)	23.1 vs. 6.1	0.022
Original disease		
Non-cirrhosis ($n = 38$) vs. cirrhosis ($n = 171$)	10.5 vs. 6.4	0.377
Number of LDLT		
≥ 2 ($n = 8$) vs. 1 ($n = 201$)	25.0 vs. 6.5	0.046
PELD or MELD		
≥ 20 ($n = 44$) vs. < 20 ($n = 165$)	18.2 vs. 4.2	0.001
ABO compatibility		
Incompatible ($n = 33$) vs. others ($n = 176$)	6.1 vs. 7.4	0.787
GV/SLV		
<40 % ($n = 10$) vs. ≥ 40 % ($n = 199$)	0.0 vs. 7.5	0.368
Graft type		
Lateral segment graft ($n = 145$) vs. others ($n = 64$)	4.7 vs. 8.3	0.354
Operation time		
≥ 20 h ($n = 36$) vs. < 20 h ($n = 173$)	5.6 vs. 7.5	0.678
Cold ischemic time		
≥ 2 h ($n = 103$) vs. < 2 h ($n = 106$)	8.7 vs. 5.7	0.389
Warm ischemic time		
≥ 1 hr ($n = 81$) vs. < 1 hr ($n = 128$)	8.6 vs. 6.3	0.514
Blood loss volume		
≥ 100 ml/kg ($n = 69$) vs. < 100 ml/kg ($n = 140$)	10.1 vs. 5.7	0.243
Transfusion volume		
≥ 100 ml/kg ($n = 92$) vs. < 100 ml/kg ($n = 117$)	12.0 vs. 3.4	0.018
Post-transplant complications variables		
Hepatic vein complications		
Yes ($n = 11$) vs. No ($n = 198$)	18.0 vs. 6.6	0.146
Portal vein complications		
Yes ($n = 26$) vs. No ($n = 183$)	7.7 vs. 7.1	0.913
Biliary strictures		
Yes ($n = 35$) vs. No ($n = 174$)	14.3 vs. 5.7	0.074
Intra-abdominal abscess		
Yes ($n = 14$) vs. No ($n = 195$)	14.3 vs. 6.7	0.286
Post-transplant laparotomy except for HAC treatment		
Yes ($n = 19$) vs. No ($n = 190$)	26.3 vs. 5.3	<0.001
Acute cellular rejection		
Yes ($n = 86$) vs. No ($n = 123$)	7.0 vs. 7.3	0.924
Cytomegalovirus infection		
Yes ($n = 72$) vs. No ($n = 137$)	5.6 vs. 8.0	0.511
Post-transplant lymphoproliferative disorder		
≥ 30 IU ($n = 49$) vs. < 30 IU ($n = 40$)	0.0 vs. 7.3	0.575
Hepatic artery variables		
Number of anastomosis		
Two anastomosis ($n = 14$) vs. one anastomosis ($n = 195$)	0.0 vs. 7.7	0.281
Diameter of artery		
<2.0 mm ($n = 57$) vs. ≥ 2.0 mm ($n = 152$)	8.8 vs. 6.6	0.585
Anastomotic technique		
Extra-anatomical reconstruction ($n = 3$) vs. anatomical ($n = 206$) ^a	66.7 vs. 6.6	<0.001

GV/SLV ratio of graft volume to standard liver volume, HAC hepatic artery complications, LDLT living donor liver transplantation, MELD model for end-stage liver disease, PELD pediatric end-stage liver disease

^a Extra-anatomical reconstruction; hepatic arterial reconstruction using an interposition graft and the recipient jejunal artery

Table 4 Risk factors for hepatic artery complication (HAC) after living donor liver transplantation (LDLT): multivariate analysis

Variables	Odds ratio	95% CI	P-value
Body weight			
<6 kg vs. ≥6 kg	3.05	0.53–17.43	0.211
Number of LDLT			
≥2 vs. 1	3.70	0.44–31.23	0.229
PELD or MELD			
≥20 vs. <20	4.78	1.27–17.96	0.020
Transfusion volume			
≥100 ml/kg vs. <100 ml/kg	1.19	0.30–4.82	0.805
Post-transplant laparotomy except for HAC treatment			
Yes vs. No	5.78	1.41–23.66	0.015
Hepatic artery anastomotic technique			
Extra-anatomical reconstruction vs. anatomical	70.67	4.60–1,085.22	0.002

CI confidence interval, HAC hepatic artery complications, LDLT living donor liver transplantation, MELD model for end-stage liver disease, PELD pediatric end-stage liver disease

intervention group was significantly higher than that of the surgical intervention group ($P = 0.029$).

Discussion

Hepatic artery complications can still occur after LT, despite the recent improvements and innovations in surgical techniques [16], and it can occasionally lead to graft liver failure or even death. However, few studies have analyzed the risk factors for HAC in pediatric recipients, and no consensus has yet been reached. Most of the previous studies of the risk factors for HAC in children have included only a small number of cases, but the available data indicate that there is a high degree of HAC-related morbidity in pediatric LT cases. Therefore, in any investigation of the risk factors for HAC, the total number of pediatric cases examined must be considered. In the present study, we investigated a much larger number of pediatric cases after LDLT in comparison with the reports from other pediatric LDLT facilities.

The causes of HAC are multifactorial, but in pediatric LT recipients, HAC is often related to the techniques used in transplant surgery [1–3]. Although LT in small infants yields similar outcomes to those in older recipients [3, 17, 18], it is more challenging technically because of the smaller vascular structures. Additionally, pediatric LDLT is associated with problems of vessel size mismatch between the pediatric recipients and adult donors, as well as technical difficulties arising from insufficient vascular pedicles for reconstruction. The vessels of pediatric recipients with metabolic

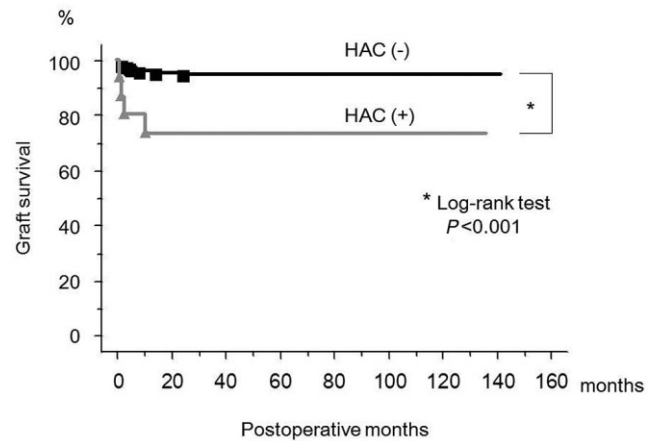


Fig. 5 The graft survival of the recipients with and without hepatic arterial complication (HAC). The log-rank test showed that the accumulated graft survival rate of recipients without HAC was significantly higher than that of recipients with HAC ($P < 0.001$)

disease, or those of neonatal recipients, are weaker and thinner than those of pediatric recipients with cirrhotic disease. Furthermore, pediatric LDLT is associated with problems related to the size mismatch between the graft and the small abdominal cavity of the recipient, accompanied by technical difficulties arising from the anastomotic field used for reconstruction. Consequently, recipients with a low body weight undergoing LDLT are at an increased risk of developing HAC. However, in the present study, low body weight and non-cirrhotic disease were not significant risk factors associated with the development of HAC. This supports the effectiveness of the selection of the recipient's hepatic artery and anastomotic field used in our surgical technique. We think that, for a small vessel diameter and narrow abdominal cavity, such as those in neonates, it is effective to perform the reconstruction using the branch patch technique and to keep the anastomotic field in the dorsal location of the portal vein anastomosis (Fig. 3).

Primary LT was associated with a HAC incidence of 1.6%, which increased to 4.8% and 12.5% for the second and the third LT, respectively [3]. When re-LT becomes necessary, hepatic arterial reconstruction can be extremely difficult because of the presence of severe inflammation around the native hepatic artery and the lack of an adequate artery for reconstruction. Frequently, the native recipient hepatic artery is in poor condition, requiring the use of an alternative as an extra-anatomical hepatic artery. In such cases, the recipient splenic artery, right gastroepiploic artery, or jejunal artery of the Roux-en-Y limb can be used safely for hepatic arterial reconstruction [9, 19–23]. On the other hand, hepatic arterial reconstruction using an interposition graft can be selected when the native recipient artery around the hepatic arterial anastomotic position cannot be used [24–26]. However, there are strong arguments suggest-

Table 5 Treatment and outcome of recipients with hepatic artery complications (HAC)

Case	Original disease	Age (months)/sex/BW (kg)	PELD score	Post-transplant laparotomy before treatment of HAC	Extra-anatomical reconstruction	Onset of HAC (pod)	Cause of HAC	Treatment for HAC	Outcome of treatment	Recipient outcome
1	BA	10/F/8.1	25.0	+	-	9	Anastomotic stenosis	Re-anastomosis using interposition graft (donor left RA)	Success	Alive (POM137)
2	AD	20/F/7.9	24.1	+	-	16	Anastomotic stenosis	Re-anastomosis	Success (NAS)	Graft loss due to HVS (POM11)
3	BA	12/F/6.3	29.5	-	-	17	Compression due to hematoma	Removal of hematoma	Success	Dead due to bowel perforation (POD48)
4	BA	31/F/11.8	8.7	-	-	24	Spasm due to abscess	Removal of abscess	Success	Success
5	BA	26/F/12.6	8.5	-	-	8	Anastomotic stenosis	Surgical thrombectomy	Success	Alive (POM131)
6	FHF	62/M/16.3	11.2	-	-	5	Anastomotic stenosis	Surgical thrombectomy	Success	Graft loss due to HVS (POD25)
7	BA	8/M/6.8	25.4	-	-	5	Anastomotic stenosis	Surgical thrombectomy	Success (NAS)	Dead due to HPS (POD80)
8	BA	14/F/7.5	4.4	-	-	8	Anastomotic stenosis	Endovascular balloon angioplasty	Recurrence	Alive (POM107)
9	BA	10/F/6.5	8.6	-	Interposition graft using donor GEA	3	Anastomotic stenosis	Surgical thrombectomy	Success	Alive (POM101)
10	BA	9/F/7.5	37.3	-	-	5	Anastomotic stenosis	Endovascular balloon angioplasty	Recurrence	Recurrence
11	BA	8/F/5.8	19.8	+	-	10	Anastomotic stenosis	Endovascular balloon angioplasty	Success (NAS)	Success (NAS)
12	NH	0/F/2.6	22.6	-	-	6	Anastomotic stenosis	Endovascular balloon angioplasty	Failure	Alive (POM72)
13	BA	6/M/6.7	26.0	-	-	7	Anastomotic stenosis	Endovascular balloon angioplasty under laparotomy	Success	Success
14	Graft liver failure	37/F/10.7	14.1	-	Anastomosis using JA of RY jejunum	8	Anastomotic stenosis due to kinking	Endovascular balloon angioplasty	Success (NAS)	Alive (POM45)
15	LC	11/F/3.1	27.9	+	-	4	Anastomotic stenosis due to kinking	Endovascular stent placement	Recurrence	Alive (POM44)
						9	Compression due to hematoma	Removal of hematoma	Success	Alive (POM40)
						5	Compression due to hematoma	Removal of hematoma	Success	Alive (POM40)

AD Alagille syndrome, BA biliary atresia, BW body weight, FHF fulminant hepatic failure, GEA gastroepiploic artery, HPS hemophagocytic syndrome, HVS hepatic vein stenosis, JA jejunal artery, LC liver cirrhosis, NAS non-anastomotic biliary stricture, NH neonatal hemochromatosis, PELD pediatric end-stage liver disease, POD postoperative day, POM postoperative month, RA radial artery, RY Roux-en-Y

Table 6 Comparisons of recipients who underwent surgical and endovascular interventions for hepatic artery complications (HAC)

Variables	Surgical interventions (<i>n</i> = 8: 11 times)	Endovascular interventions (<i>n</i> = 7: 13 times)	<i>P</i> -value
Age at LDLT (months)	16 (9–62)	8 (0–37)	0.073
Body weight at LDLT (kg)	8.0 (3.1–16.0)	6.7 (2.6–10.7)	0.118
PELD score	24.6 (8.5–37.3)	19.8 (4.4–26.0)	0.355
Extra-anatomical HA reconstruction (%)	0.0	28.6	0.104
Post-transplant laparotomy (%)	37.5	14.3	0.310
Onset of HAC (POD)	7 (3–24)	8 (3–27)	0.931
Pre-HAC treatment AST (IU/l)	138 (65–2,065)	66 (23–667)	0.016
Pre-HAC treatment ALT (IU/l)	405 (108–1,582)	255 (86–1,376)	0.125
Post-HAC treatment AST (IU/l)	710 (73–2,160)	66 (24–1,107)	0.022
Post-HAC treatment ALT (IU/l)	817 (186–2,720)	301 (78–1,797)	0.064
Recurrence rate of HAC (%)	18.2	46.2	0.147
Post-HAC treatment biliary complications (%)	25.0	42.9	0.464
Post-HAC treatment graft survival rate (%)	50.0	100.0	0.029
Post-HAC treatment recipient survival rate (%)	75.0	100.0	0.155

ALT alanine amino transferase, *AST* aspartate amino transferase, *HA* hepatic artery, *LDLT* living donor liver transplantation, *PELD* pediatric end-stage liver disease, *POD* postoperative day

ing that use of an arterial conduit is a risk factor for HAC [3]. Hepatic arterial reconstruction using an interposition graft necessitates two micro-vascular anastomoses, increasing the complexity and duration of the procedure, and increasing the risk of HAC [24–26]. Thus, hepatic arterial reconstruction using an interposition graft should be avoided whenever possible. In the present study, both re-LDLT and the use of an interposition graft were significant risk factors for HAC, thus confirming the importance of the appropriate selection of the recipient's hepatic artery during re-LT.

An early diagnosis and treatment for HAC after pediatric LDLT are essential, and there are currently two major therapeutic options for HAC: surgical and endovascular interventions. Endovascular interventions have emerged as an attractive and less invasive alternative to surgical interventions in recent years [7–14]. However, endovascular interventions remain controversial in view of the potential risks of hemorrhage in the early postoperative period and their uncertain long-term patency. We have reported that endovascular interventions in the early postoperative period were safer and less invasive than surgical interventions [9–11], and other transplant surgeons have reported that endovascular interventions can lead to a successful mid-term patency [12–14]. Endovascular interventions can be used for both the early diagnosis and treatment for HAC, because percutaneous transfemoral angiography can be carried out more easily than laparotomy, and endovascular interventions can be carried out immediately. Therefore, endovascular interventions have been the first choice for the treatment of HAC at our department since December 2004. We believe that the only exclusion criterion should be the

presence of compressive or spastic artery hypoperfusion due to hematoma or abscess, and that age should not be considered a contraindication.

In the present study, the serum AST levels pre- and post-treatment for HAC were significantly higher in the surgical intervention group than in the endovascular intervention group ($P = 0.016$ and $P = 0.022$, respectively). This is likely because endovascular interventions are more protective for the graft than surgical interventions. The cumulative graft survival rate of recipients without HAC was significantly higher than that of recipients with HAC ($P < 0.001$; Fig. 5). However, HAC did not lead to the loss of any grafts in our cases. On the other hand, the graft survival rate of the endovascular intervention group was significantly higher than that of the surgical intervention group ($P = 0.029$; Table 6). Therefore, endovascular interventions may make a more significant contribution to the protection actions of the graft liver and prevention of life-threatening post-transplant complications than do surgical interventions, likely because it allows for earlier treatment of HAC. Our present experience supports the effectiveness of endovascular interventions for HAC; however, both further accumulation of cases and long-term observation of cases are needed to confirm our present findings.

In conclusion, it is possible to perform LDLT safely by ensuring the appropriate selection of the recipient's hepatic artery and anastomotic field, even in pediatric recipients with a high risk of HAC. In addition, it is important for recipients with a PELD score ≥ 20 , post-transplant laparotomy except for HAC treatment and with extra-anatomical hepatic artery reconstruction to receive strict post-transplant management to monitor them for the development of HAC

and to help prevent HAC, such as by providing stronger anticoagulation treatment and more frequent Doppler ultrasonography examinations. It is possible to prevent graft loss by ensuring an early diagnosis and providing adequate treatment. When HAC is suspected after LDLT, endovascular intervention can be a less invasive method for treating HAC than surgical intervention, and can be performed as an early treatment.

Conflict of interest None declared.

Author contributions Study design: Yuhhiro Sanada. Acquisition of data: Taiichi Wakiya, Shuji Hishikawa, Yuta Hirata, Naoya Yamada, Noriki Okada, Yoshiyuki Ihara, and Taizen Urahashi. Analysis and interpretation: Yuhhiro Sanada and Taiichi Wakiya. Manuscript drafted by: Yukihiro Sanada. Revision: Koichi Mizuta and Eiji Kobayashi. Statistical advice: Koichi Mizuta.

References

- Bekker J, Ploem S, de Jong KP. Early hepatic artery thrombosis after liver transplantation: a systematic review of the incidence, outcome and risk factors. *Am J Transplant*. 2009;9:746–57.
- Shirouzu Y, Kasahara M, Morioka D, Sakamoto S, Taira K, Uryuhara K, et al. Vascular reconstruction and complications in living donor liver transplantation in infants weighing less than 6 kilograms: the Kyoto experience. *Liver Transpl*. 2006;12:1224–32.
- Oh CK, Pelletier SJ, Sawyer RG, Dacus AR, McCullough CS, Pruett TL, et al. Uni- and multi-variate analysis of risk factors for early and late hepatic artery thrombosis after liver transplantation. *Transplantation*. 2001;71:767–72.
- Ackermann O, Branchereau S, Franchi-Abella S, Pariente D, Chevret L, Debray D, et al. The long-term outcome of hepatic artery thrombosis after liver transplantation in children: role of urgent revascularization. *Am J Transplant*. 2012;12:1496–503.
- Warnaar N, Polak WG, de Jong KP, de Boer MT, Verkade HJ, Sieders E, et al. Long-term results of urgent revascularization for hepatic artery thrombosis after pediatric liver transplantation. *Liver Transpl*. 2010;16:847–55.
- Nishida S, Kato T, Levi D, Naveen M, Thierry B, Vianna R, et al. Effect of protocol Doppler ultrasonography and urgent revascularization on early hepatic artery thrombosis after pediatric liver transplantation. *Arch Surg*. 2002;137:1279–83.
- Uchida Y, Sakamoto S, Egawa H, Ogawa K, Ogura Y, Taira K, et al. The impact of meticulous management for hepatic artery thrombosis on long-term outcome after pediatric living donor liver transplantation. *Clin Transplant*. 2009;23:392–9.
- Singhal A, Stokes K, Sebastian A, Wright HI, Kohli V. Endovascular treatment of hepatic artery thrombosis following liver transplantation. *Transpl Int*. 2010;23:245–56.
- Wakiya T, Sanada Y, Mizuta K, Umehara M, Urahashi T, Egami S, et al. Hepatic artery reconstruction with the jejunal artery of the Roux-en-Y limb in pediatric living donor liver re-transplantation. *Pediatr Transplant*. 2012;16:E86–89.
- Wakiya T, Sanada Y, Mizuta K, Umehara M, Urahashi T, Egami S, et al. Endovascular interventions for hepatic arterial complications immediately after pediatric liver transplantation. *Transplant Int*. 2011;24:984–90.
- Wakiya T, Sanada Y, Mizuta K, Urahashi T, Ihara Y, Yamada N, et al. A comparison of open surgery and endovascular intervention for hepatic artery complications after pediatric liver transplantation. *Transplant Proc*. 2013;45:323–9.
- Hamby BA, Ramirez DE, Loss GE, Bazan HA, Smith TA, Bluth E, et al. Endovascular treatment of hepatic artery stenosis after liver transplantation. *J Vasc Surg*. 2013;57:1067–72.
- Maruzzelli L, Miraglia R, Caruso S, Milazzo M, Mamone G, Gruttadauria S, et al. Percutaneous endovascular treatment of hepatic artery stenosis in adult and pediatric patients after liver transplantation. *Cardiovasc Intervent Radiol*. 2010;33:1111–19.
- Sabri SS, Saad WE, Schmitt TM, Turba UC, Kumer SC, Park AW, et al. Endovascular therapy for hepatic artery stenosis and thrombosis following liver transplantation. *Vasc Endovascular Surg*. 2011;45:447–52.
- Mizuta K, Yasuda Y, Egami S, Sanada Y, Wakiya T, Urahashi T, et al. Living donor liver transplantation for neonates using segment 2 monosegment graft. *Am J Transpl*. 2010;10:2547–52.
- Todo S, Fukawa H, Kamiyama T. How to prevent and manage biliary complications in living donor liver transplantation? *J Hepatol*. 2005;43:22–7.
- Broelsch CE, Whittington PF, Emond JC, Heffron TG, Thistlethwaite JR, Stevens L, et al. Liver transplantation in children from living related donors: surgical techniques and results. *Ann Surg*. 1991;214:428–37.
- Noujaim HM, Mayer DA, Buckles JA, Beath SV, Kelly DA, McKiernan PJ, et al. Techniques for and outcome of liver transplantation in neonates and infants weighing up to 5 kilograms. *J Pediatr Surg*. 2002;37:159–64.
- Wang C, Lin T, Chen C, Concejero A, Iyer S, Chiang Y. Arterial reconstruction in hepatic artery occlusions in adult living donor liver transplantation using gastric vessels. *Surgery*. 2008;143:686–90.
- Figueras J, Pare's D, Aranda H, Rafecas A, Fabregat J, Torras J, et al. Results of using the recipient's splenic artery for arterial reconstruction in liver transplantation in 23 patients. *Transplantation*. 1997;64:655–8.
- Tannuri U, Maksoud-Filho J, Silva M, Suzuki L, Santos MM, Gibelli NE, et al. An alternative method of arterial reconstruction in pediatric living donor liver transplantation with the recipient right gastroepiploic artery. *Pediatr Transplant*. 2006;10:101–4.
- Kasahara M, Sakamoto S, Ogawa K, Uryuhara K, Matsuoka J, Uchida Y, et al. The use of a mesenteric artery of Roux-en-Y limb for hepatic arterial reconstruction after living-donor liver transplantation. *Transplantation*. 2005;80:538.
- Uchiyama H, Shirabe K, Taketomi A, Soejima Y, Ninomiya M, Kayashima H, et al. Extra-anatomical hepatic artery reconstruction in living donor liver transplantation: can this procedure save hepatic grafts? *Liver Transpl*. 2010;16:1054–61.
- Asonuma K, Ohshiro H, Izaki T, Okajima H, Ueno M, Kodera A, et al. Rescue for rare complications of the hepatic artery in living donor liver transplantation using grafts of autologous inferior mesenteric artery. *Transpl Int*. 2004;17:639–42.
- Del Gaudio M, Grazi G, Ercolani G, Ravaioli M, Varotti G, Cescon M, et al. Outcome of hepatic artery reconstruction in liver transplantation with an iliac arterial interposition graft. *Clin Transplant*. 2005;19:399–405.
- Inomoto T, Nishizawa F, Terajima H, Shirakata Y, Yamamoto Y, Miyamoto S, et al. The use of the recipient sigmoid artery for a revision of hepatic arterial reconstruction after thrombosis in living related liver transplantation. *Transplantation*. 1995;60:881–2.